

CASE REPORT**Tuberculous Mastitis: A Case Report**

Gopal A. Pandit¹*, Sunita S. Dantkale¹, Nisha V. Thakare¹, Smita S. Pudale¹

¹Department of Pathology, Dr. V. M. Govt. Medical College, Solapur - 413001 (Maharashtra), India

Abstract:

Tuberculosis of breast is an uncommon disease clinically mimicking breast carcinoma. We present a case of a 22 years old female who complained of a breast mass and axillary swelling of three months duration. Clinically she was diagnosed as having phyllodes tumour. The breast mass ultrasonography revealed a benign cystic hypoechoic lesion. Grossly the excised mass was a cyst containing serous fluid along with a small solid yellowish white nodule with foci of caseation. The axillary lymph nodes also showed caseous necrosis. A definitive diagnosis of tuberculous mastitis was reached by histological demonstration of caseating granulomas in the cyst wall and in the ipsilateral axillary lymph nodes.

Key words: Tuberculosis, breast.

Introduction:

Extra pulmonary tuberculosis occurring in breast is relatively rare despite one third of world's population being infected with tubercle bacilli [1]. Tuberculosis of breast was first documented by Sir Astley Cooper in 1829 [1, 2]. Though cases of tuberculous mastitis have been reported worldwide, they are reported more frequently in India, probably due to a high prevalence of tuberculous infection [1]. Breast tuberculosis is paucibacillary and consequently microscopy, culture and nucleic acid amplification tests like PCR do not have the same diagnostic utility as they do in pulmonary tuber-

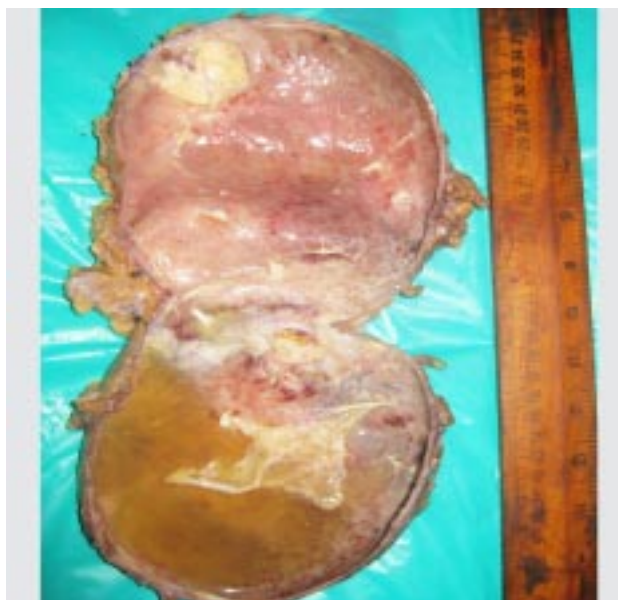
culosis [3]. We present here a case of secondary tuberculous mastitis which clinically mimicked malignancy.

Case Report:

A 22 years old HIV negative female presented with lump in her left breast since 3 months. She did not have history of pain, trauma, fever, night sweats, weight loss or respiratory symptoms. Patient was unmarried and had a history of some psychiatric illness and was on treatment for the same. She had no past history of tuberculosis or any other breast lesion. There was no history of tuberculosis in her family.

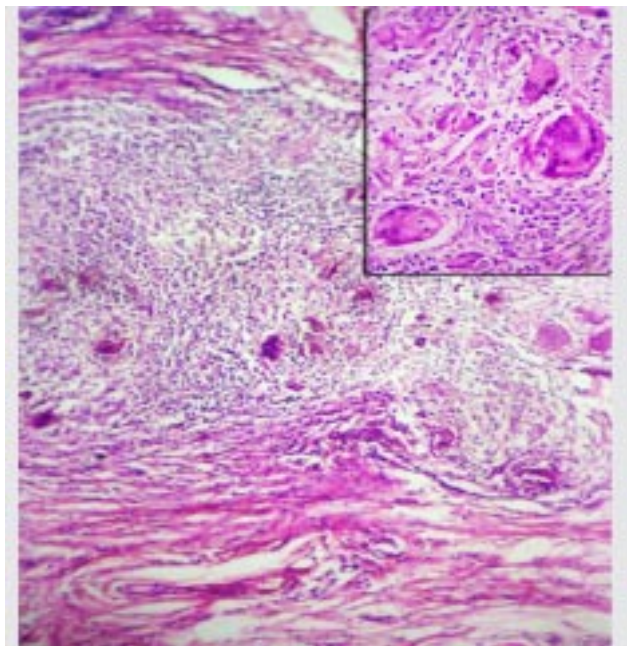
Legends for Photographs:**Photograph 1: Gross picture of Cut Opened Tuberculous Breast Cyst.**

Cavity contains serous fluid. Mural nodule 2 x 2 cm shows caseous necrosis.



Photograph 2: Photomicrograph Showing Cyst Wall with Multiple Caseating Granulomas (100x, H and E).

Inset shows caseating granulomas with many Langhans type giant cells. (400x, H and E)



On clinical examination, she had a 13 x 13 x 8 cm mass in her left breast occupying most of the upper and lower outer quadrants. Nipple discharge and involvement of the overlying skin was absent. Significant left axillary lymphadenopathy was noted. Three discrete lymph nodes were palpable, the largest measuring 5 x 3 x 2 cm and smallest measuring 2 x 2 x 1 cm. A clinical diagnosis of phyllodes tumour was made. Patient also had a cervical swelling with a discharging sinus which wasn't investigated previously.

Ultrasonography of the mass revealed a hypoechoic cystic lesion of 11 x 11 x 5 cm with thin wall (4mm) and few thin septae (1mm) along with an isoechoic mural nodule of 3 x

1.5 cm in its inferolateral aspect. Mammography was not done. Her total leucocyte count was 14,000/mm³ (71 % being polymorphs) while her ESR was 110. On FNAC of the breast mass only a thin serous fluid with few cyst macrophages was aspirated. Her chest X ray did not reveal any abnormality. An excision of the breast mass along with ipsilateral axillary lymph nodes was performed.

Gross:

The breast mass was 10 x 10 x 3 cm in dimensions and was cystic in consistency. On cut opening, the mass turned out to be a unilocular cyst containing approximately 200cc serous fluid along with a solid nodule in the cyst wall showing caseation. Three axillary nodes were received, largest measuring 4 x 3 x 2 cm. Cut surfaces of all the lymph nodes showed caseous necrosis.

Microscopy:

Sections from the cyst wall, solid area of the cyst wall and all the lymph nodes showed granulomas composed of epithelioid cells & Langhans giant cells surrounded by lymphocytes along with foci of caseous necrosis. Sections were negative for acid fast bacilli on ZN stain.

Discussion:

The overall incidence of tuberculous mastitis is reported to be 0.1% of all breast lesions. In developing countries this constitutes approximately 3% of surgically treated breast diseases [4, 5]. Breast and skin are considered to be rare sites of extrapulmonary mycobacterial infection comprising 0.1 - 0.5 % of all cases of tuberculosis [5].

The age incidence is between 20 - 50 years (reproductive age group) [1, 2, 5]. The various risk

factors considered to be associated with tuberculous mastitis are multiparity, lactation, trauma, immunosuppression, past history of suppurative mastitis, pulmonary tuberculosis and tuberculous lymphadenitis involving the cervical, axillary or mediastinal nodes [1, 5, 6].

Primary as well as secondary tuberculosis rarely affects the breast, as mammary tissue appears to be inhospitable site for the survival and multiplication of tubercle bacilli [5, 7]. Mammary tuberculosis may be primary when no demonstrable tuberculous focus exists elsewhere in the body. Primary infection of breast may occur through skin abrasions or through duct openings on the nipple [7]. Secondary tuberculous infection occurs when there is a co-existing tuberculous lesion elsewhere in the body such as tuberculosis of the lung, ribs and lymph nodes. In these cases, majority of the times spread occurs through contiguous, lymphatic or hematogenous routes. Lymphatic spread is by retrograde extension from regional lymph nodes, usually axillary but also from cervical or mediastinal nodes. This route is most common and 50 - 75% patients have involvement of axillary nodes at the time of presentation [1]. Our patient also has had axillary lymphadenopathy. So, the involvement of breast in our case is most probably secondary to tuberculous lymphadenitis.

Breast tuberculosis has been first classified into five different types by McKeown and Wilkinson as i] Nodular tuberculous mastitis ii] Disseminated/Confluent tuberculous mastitis iii] Sclerosing tuberculous mastitis iv] Tuberculous mastitis obliterans v] Acute miliary tuberculous mastitis [7]. The nodulocaseous form presents as a well circumscribed slowly

growing painless mass that progresses to involve the overlying skin and may ulcerate forming discharging sinuses. The disseminated form is characterized by multiple foci throughout the breast that later caseate leading to sinus formation with or without painful ulceration. The sclerosing variety affects older females, dominant feature being excessive fibrosis rather than caseation. It may be misdiagnosed as scirrhous carcinoma. Acute miliary tuberculous mastitis is a part of a generalized miliary tuberculosis. Tuberculous mastitis obliterans is characterised by duct infection producing proliferation of lining epithelium with marked epithelial and periductal fibrosis. Ducts are occluded and cystic spaces are produced resembling cystic mastitis [7]. Our patient also has presented with a cystic mass as has been described by D. R. Nagpaul [2] and various other authors [3, 4, 8].

The histopathological differential diagnosis of tuberculosis of breast includes other infections, sarcoidosis and granulomatous reaction to tumour. In breast tuberculosis, acid fast bacilli are identified in only 12% of patients. Hence, demonstration of caseating granulomas and Langhans giant cells in the breast tissue and involved lymph nodes may be sufficient for diagnosis [8], as has been seen in the present case.

Conclusion:

Mammary tuberculosis should be considered in the differential diagnosis of any case of clinically painful or painless breast mass, breast abscess or carcinoma in a female in the reproductive age group especially in an endemic country like ours. Recognition and differentiation of tuberculous mastitis from that of breast malignancy is absolutely necessary as

the prognosis and treatment in both the conditions differs tremendously.

References:

1. Prem Parkash Gupta, KB Gupta, Rohtas K Yadav and Dipti Agarwal. Tuberculous mastitis: a review of seven consecutive cases. *Ind J Tub* 2003; 50: 47.
2. DR Nagpaul. Breast tuberculosis. *Ind J Tub III* (1): 15-19.
3. KB Sriram, D Moffatt and R Stapledon. Tuberculosis infection of the breast mistaken for granulomatous mastitis: a case report. *Cases Journal* 2008, 1:273.
4. Teo THP, Ho GH, Chaturverdi A, Khoo BKJ. Tuberculosis of the chest wall: unusual presentation as a breast lump. *Singapore Med J* 2009; 50(3): e97-99.
5. Donya Farrokh, Fariba Rezaii Talab, Yalda Fallah Rastegar. Primary breast tuberculosis mimicking carcinoma: a case report. *Iranian Journal of Clinical Infectious Diseases* 2010; 5(4): 242-245.
6. R Khanna, GV Prasanna, P Gupta, MKumar, S Khanna, AK Khanna. Mammary tuberculosis: report on 52 cases. *Postgrad Med J* 2002; 78(921): 422-424.
7. Mallika Tewari and HS Shukla. Breast tuberculosis: diagnosis, clinical features and management. Review Article. *Indian J Med Res* 2005; 122: 103-110.
8. Leo Francis Tauro, John S. Martis, Celine George, Aroon Kamath, Geover Lobo, B. Rathnakar Hegde. Tuberculous Mastitis Presenting as Breast Abscess. *Oman Med J* 2011; 26(1): 53-55.

**Author for Correspondence: Dr. Gopal A. Pandit, Department of Pathology, Dr. V. M. Govt. Medical College, Civil Chowk, Solapur - 413003 (Maharashtra), India. Cell: 9975650862
Email: dr.g.a.pandit@gmail.com, nisha14.thakare@gmail.com.*